

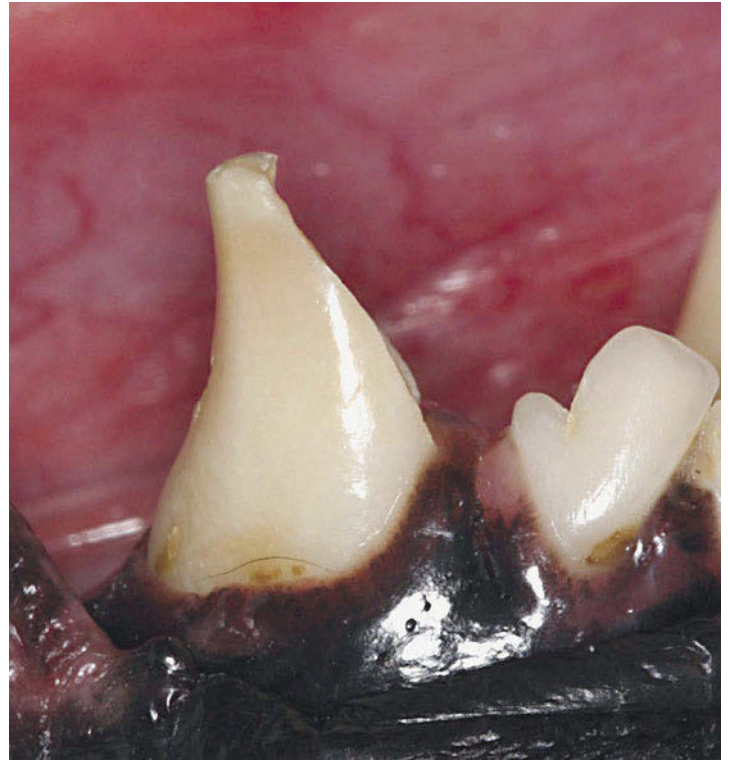
Crown Replacement

If the crown of a tooth is too heavily damaged for a composite filling, an artificial crown can be fabricated.

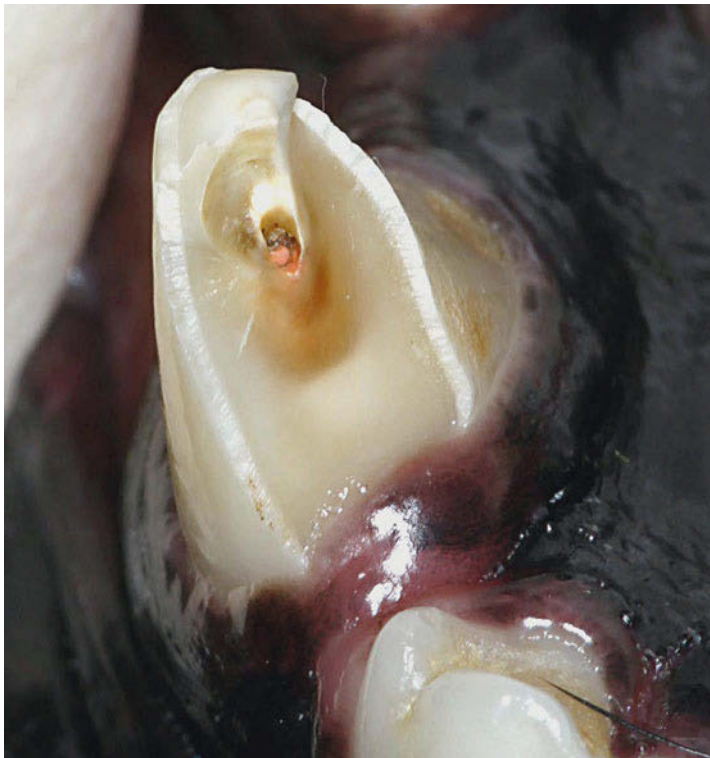16.5.1 Metal Crown for Canine Tooth

Current Case

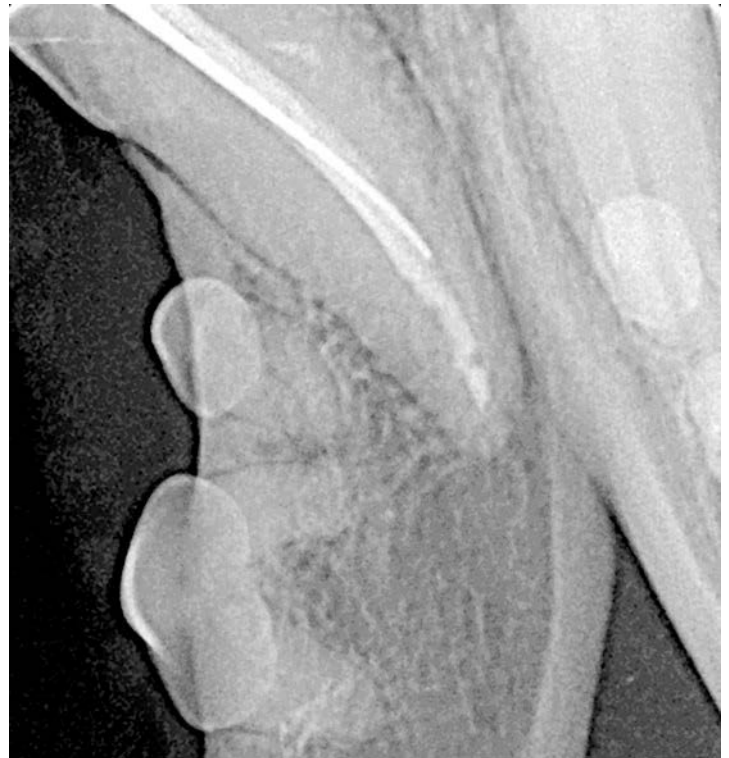
The following figures show a case in which a crown replacement is indicated (► Fig. 16.175, ► Fig. 16.176, ► Fig. 16.177).



► Fig. 16.176 Loss of the mesial crown. The lateral view clearly shows the loss of the mesial crown section.



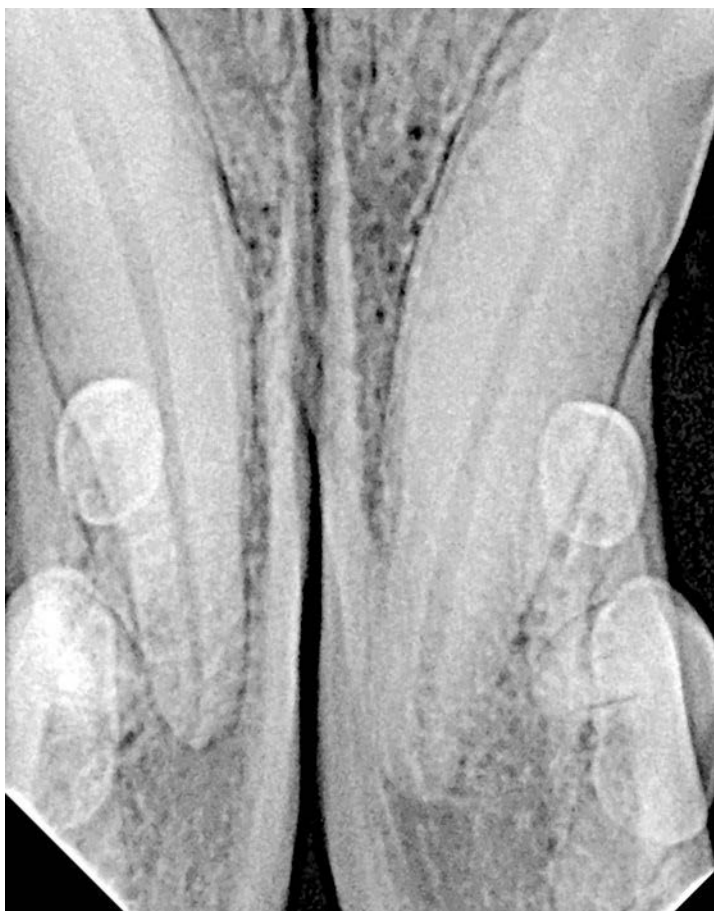► Fig. 16.175 Rupture of the coronal filling. In many cases, after root canal therapy of a canine tooth, composite may be used to seal it coronally. Considering that a dog can fracture a healthy canine tooth, however, it can obviously also re-fracture a tooth that had previous root canal therapy or is brittle. The fracture runs mesially up into the subgingival area. The root canal filling is exposed.



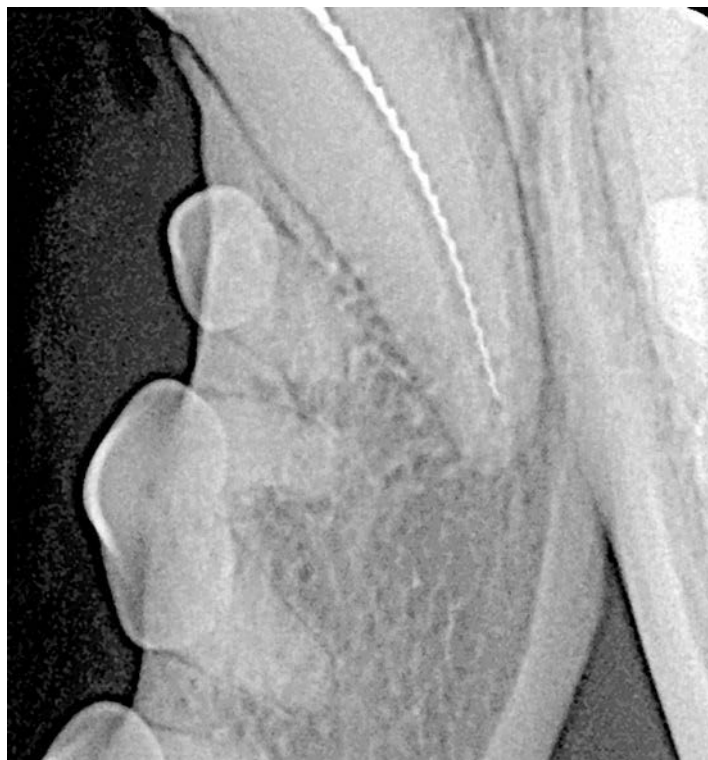► Fig. 16.177 Radiograph of the old root canal filling of tooth 404. Radiographically, a leaking root canal filling is shown.

Root Canal Therapy

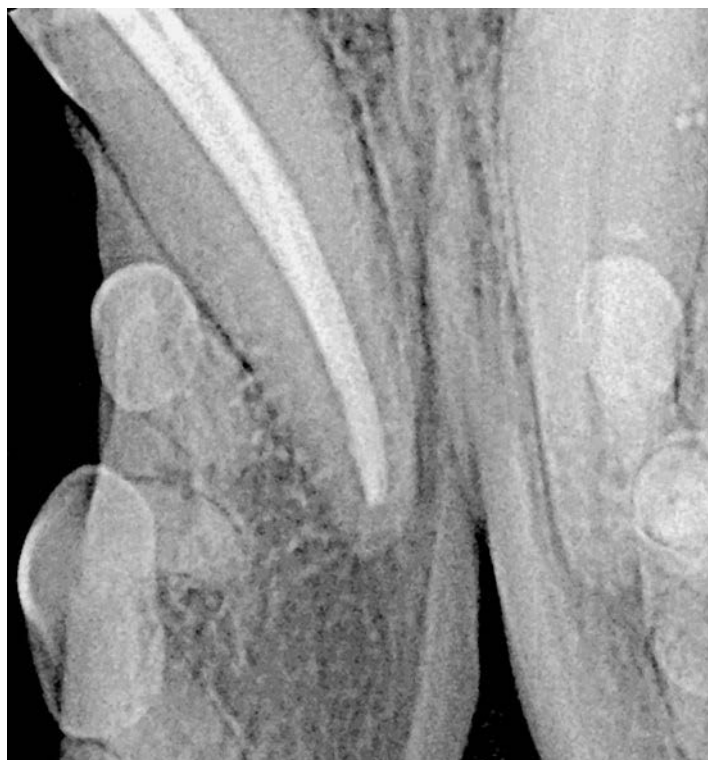In order to fit a tooth with a metal crown, the tooth must be healthy. Thus, the root canal filling must first be restored (► Fig. 16.178, ► Fig. 16.179, ► Fig. 16.180).



► Fig. 16.178 Radiograph after the old root canal filling is removed. A radiograph ensures that all residual parts of the filling have been removed.



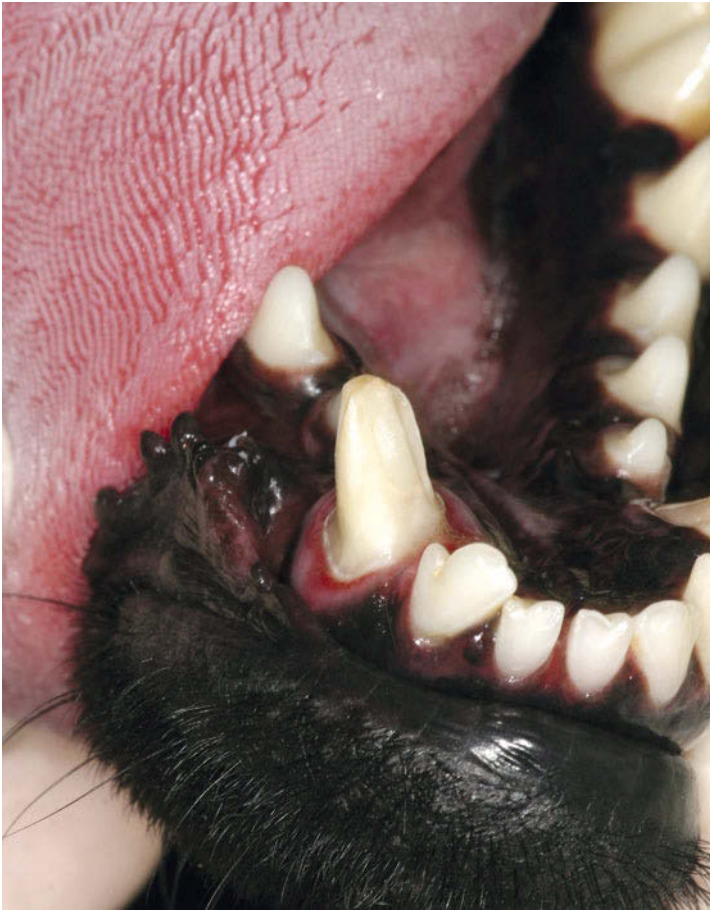► Fig. 16.179 Measurement radiograph of tooth 404. A measurement radiograph is used to verify the working length.



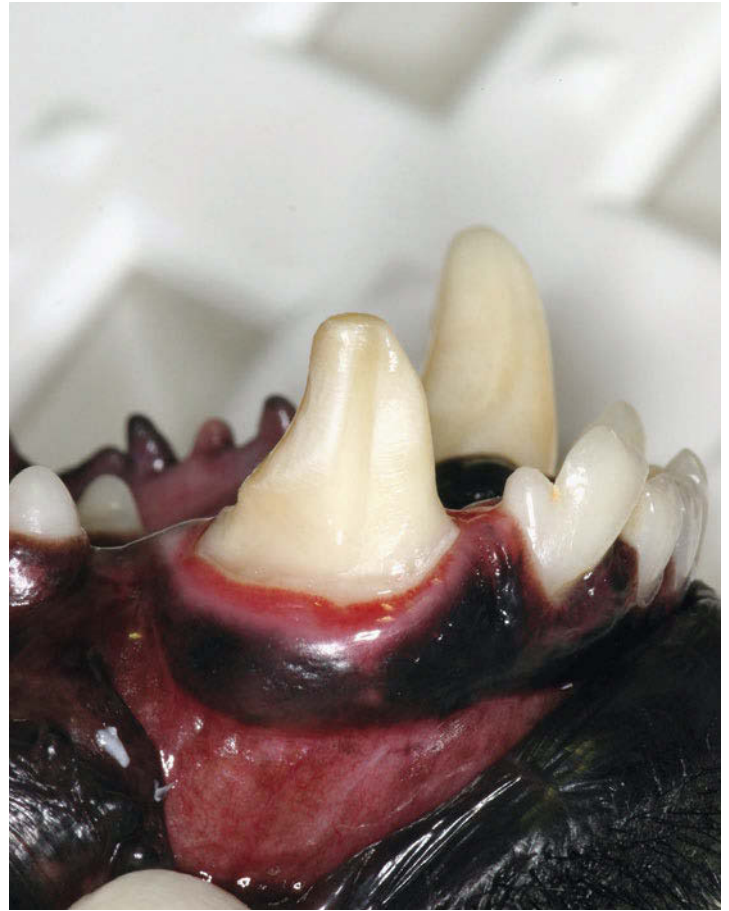► Fig. 16.180 Postoperative radiograph of the root canal filling of tooth 404. Finally, a radiograph is taken of the root canal filling.

Preparation of the Crown

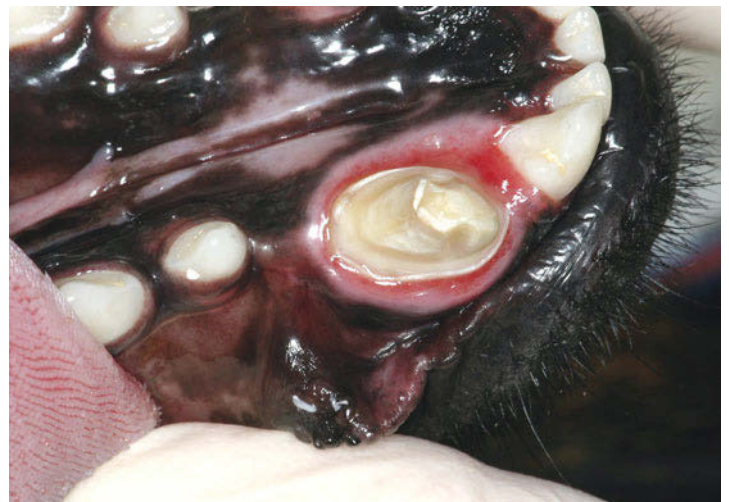The following figures and schematics show the procedure for preparing the tooth stump (► Fig. 16.181, ► Fig. 16.182, ► Fig. 16.183, ► Fig. 16.184, ► Fig. 16.185, ► Fig. 16.186).



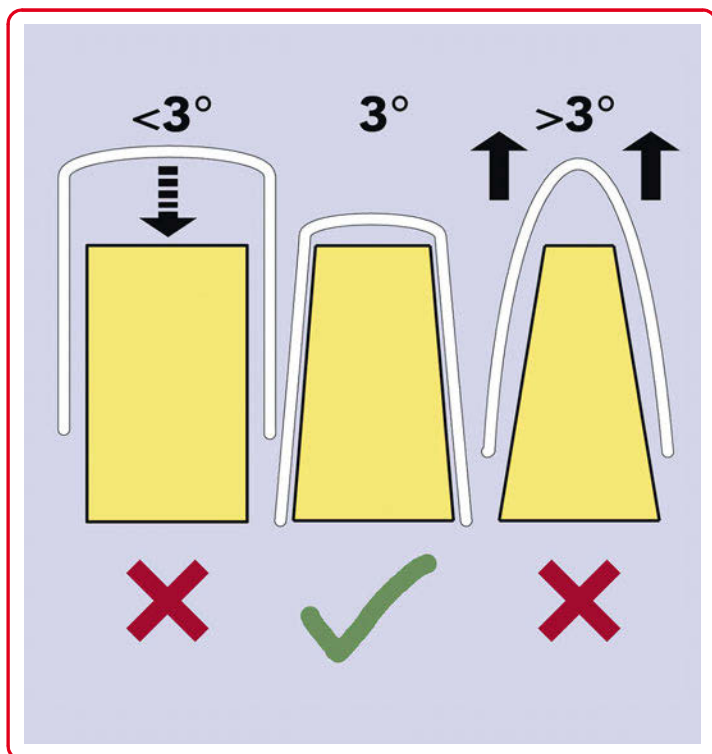
► **Fig. 16.181** Mesial view of the crown preparation of tooth 404. The tooth is prepared in a circular manner for receiving the metal crown. The white margin of the prepared border should stand out visually from the remaining stump.



► **Fig. 16.182** Lateral view of the crown preparation of tooth 404. A vertical buccal cavity that counteracts the rotational forces is additionally prepared on the very round stump.



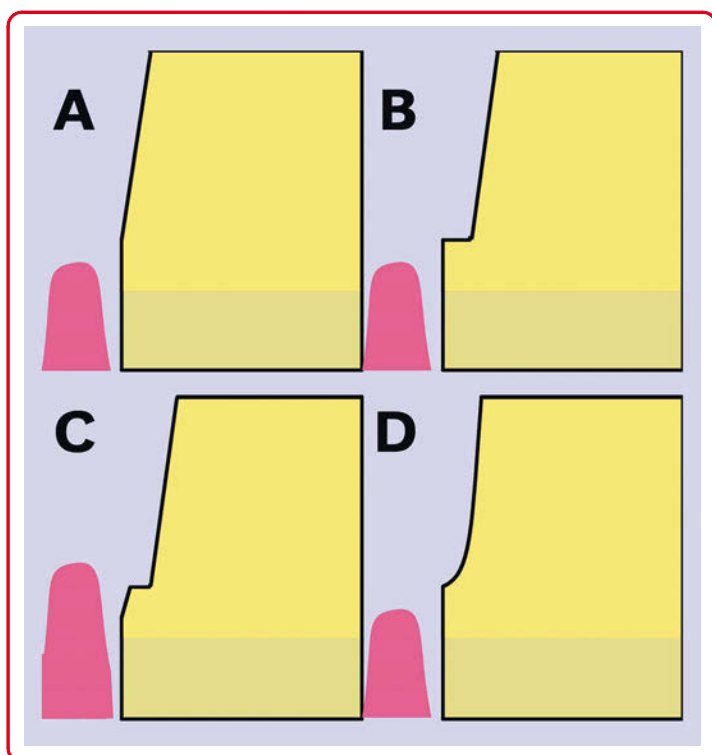
► **Fig. 16.183** Occlusal view of the crown preparation of tooth 404. In the occlusal view, the entire preparation border should be visible because it converges at the cusp. In the mesial area, the border cannot be seen clearly due to the subgingival fracture.



► **Fig. 16.184 Wall inclination of the crown.** The tooth wall requires a certain angle of inclination for receiving a crown, as shown in this schematic diagram. A wall inclination of 3° enables a crown to be fitted and cemented. However, in the case of parallel wall preparation, it cannot be placed on the stump up to the preparation border. When the inclination angle is too great, the friction of the crown is reduced and a risk of a premature crown loss arises.



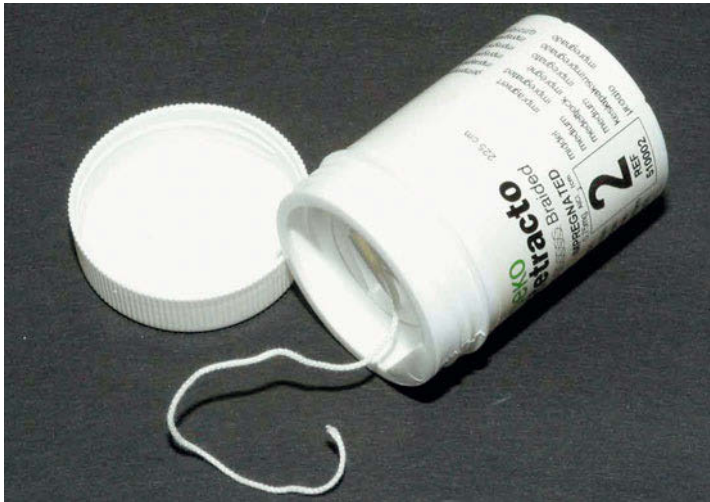► **Fig. 16.186 Cutting diamond instrument set for preparation.** Different cutting diamond designs are available for shaping the crown stump. Based on the frequently used chamfer, a torpedobur (medium form) is most convenient.



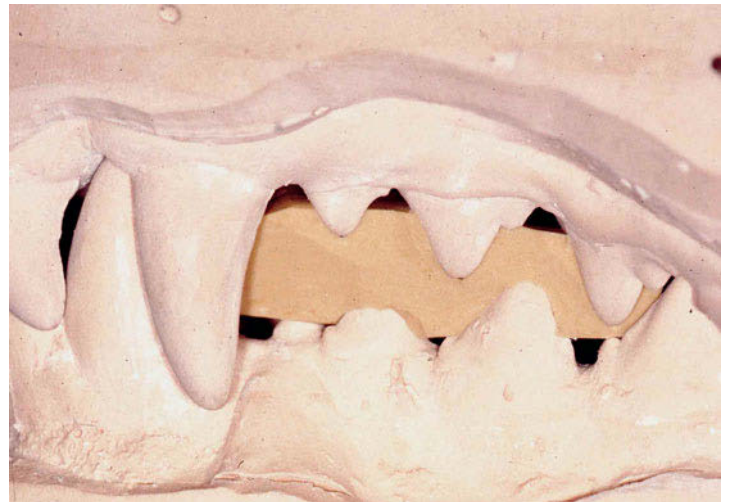
► **Fig. 16.185 Shaping the preparation border.** The crown margin may be shaped in various ways. Variant D is preferred. Chamfer preparation enables both metal and ceramic preparation. The edge is thick enough, the cement gap is thinned out in the area of the coronal margin, and the preparation border can be clinically visualized more clearly than in tangential preparation (variant A), for example.

Producing the Dental Cast

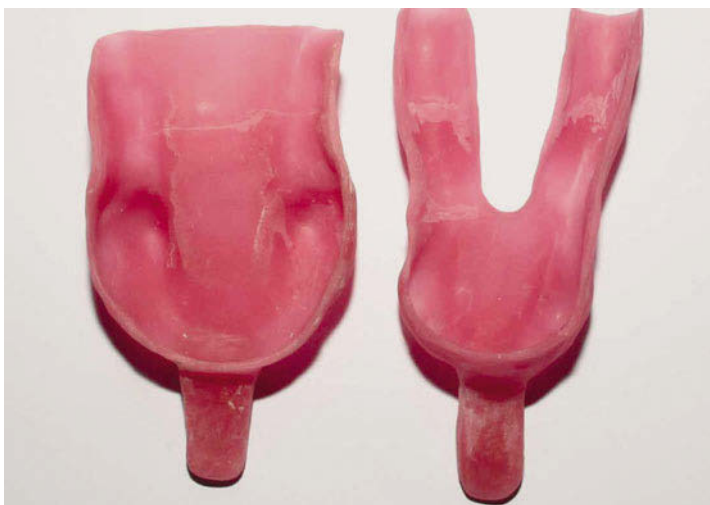An impression is taken of the teeth to make a dental cast, which is used as a model to create an artificial crown (► Fig. 16.187, ► Fig. 16.188, ► Fig. 16.189, ► Fig. 16.190).



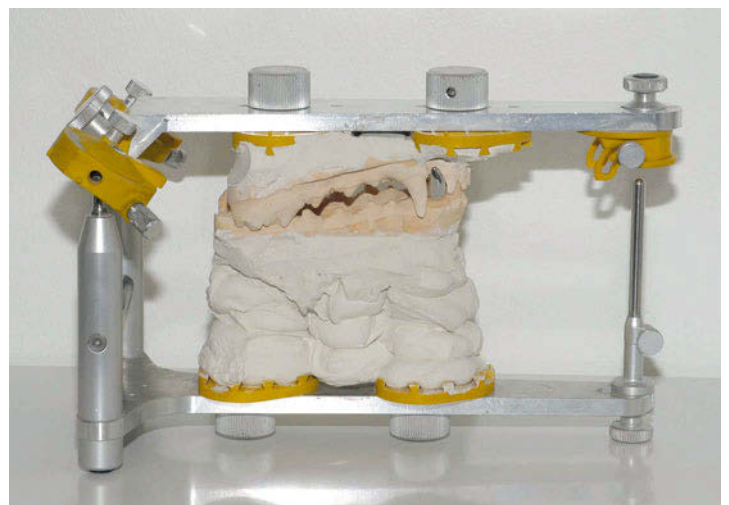► **Fig. 16.187 Retraction cord.** A retraction cord can be inserted into the gingival sulcus to dry and, if needed, separate the gingiva from the preparation border. The cord is removed just before introducing the impression material.



► **Fig. 16.189 Silicone bite registration.** The position of the maxilla and mandible between the openly interdigating premolars can be registered with a silicone bite registration. In the laboratory, the bite registration is used to fix the maxilla and mandible against each other to simulate the relative positions of the teeth when modeling the crown.



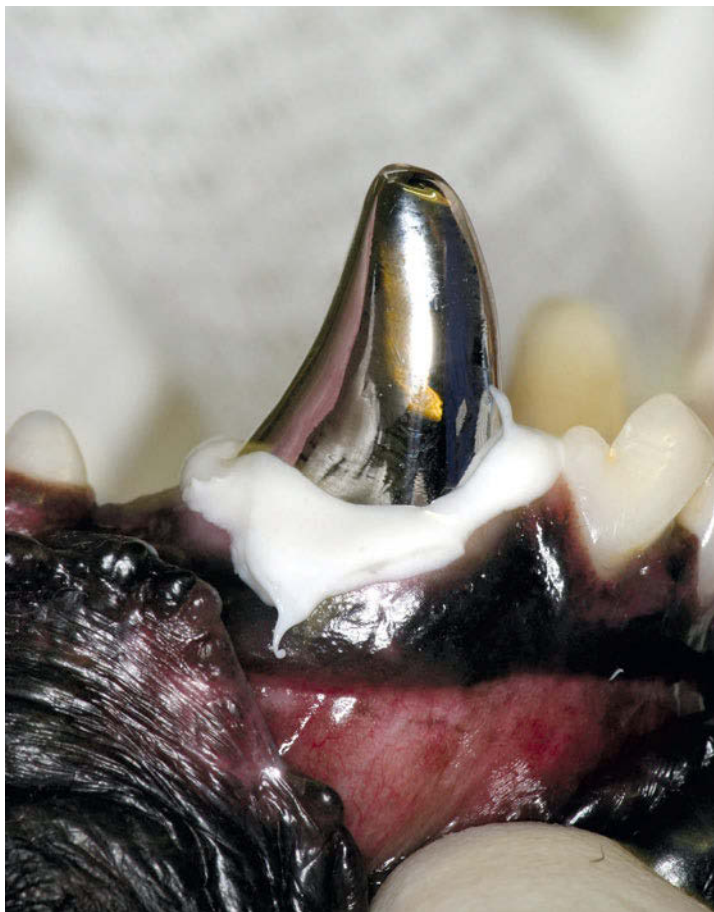
► **Fig. 16.188 Impression tray.** Since canine bites vary widely in size and shape, standardized impression trays are difficult to use. Instead, it is preferable to use impression trays that are fabricated individually for different bites. Multiple models are required to cover the entire range of variation. The tray is filled with impression silicone, the preparation edge is covered with low-viscosity silicone, and the tray and the silicone are placed in the oral cavity. After hardening, the crown impression and the impression of the counter-bite are taken to a dental laboratory for further processing.



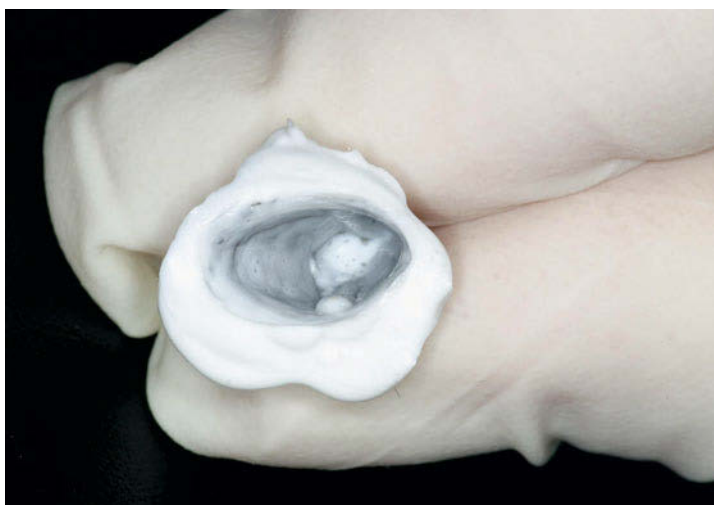► **Fig. 16.190 Articulated dental casts.** To avoid incorrect points of contact for the very tight occlusion in the canine bite, after molding, the dental casts are mounted in an articulator, which simulates occlusion in the dog's head during movement. The bite registration enables the dental casts to be placed against each other in their natural position in the articulator, and the opening of the maxilla and mandible is simulated to avoid tooth-to-tooth contact in the occlusion.

Fitting of the Crown

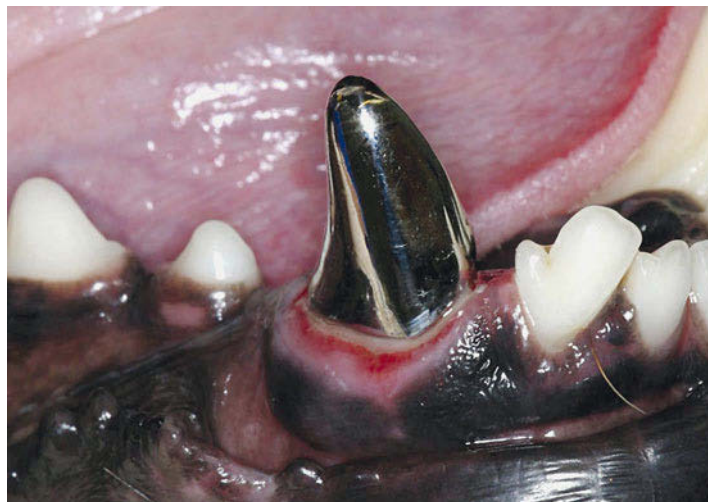In the last step, the crown is fitted onto the tooth stump (► Fig. 16.191, ► Fig. 16.192, ► Fig. 16.193, ► Fig. 16.194).



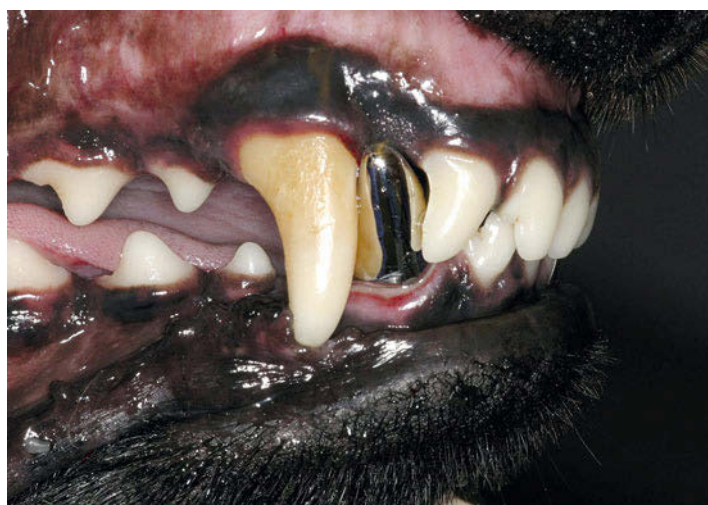► Fig. 16.191 Fitting of the crown. The fit of the crown on the stump is tested with special low-viscosity silicone.



► Fig. 16.192 Checking the crown fit. An evenly thin silicone layer shows appropriate placement of the crown on the stump. Interruption of the silicone film indicates contact between the inside of the crown and the tooth stump that must be eliminated.



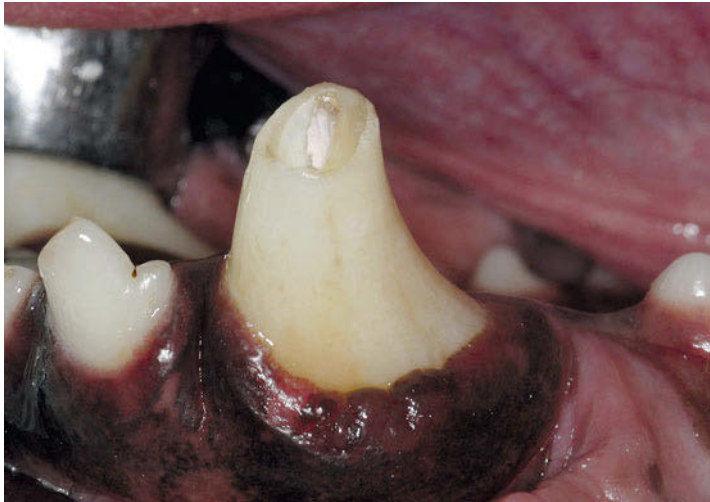► Fig. 16.193 Cemented crown on tooth 404. After fitting, the crown is permanently cemented to the tooth. Residual cement must be removed, the crown margin must be polished, and the occlusion must be checked.



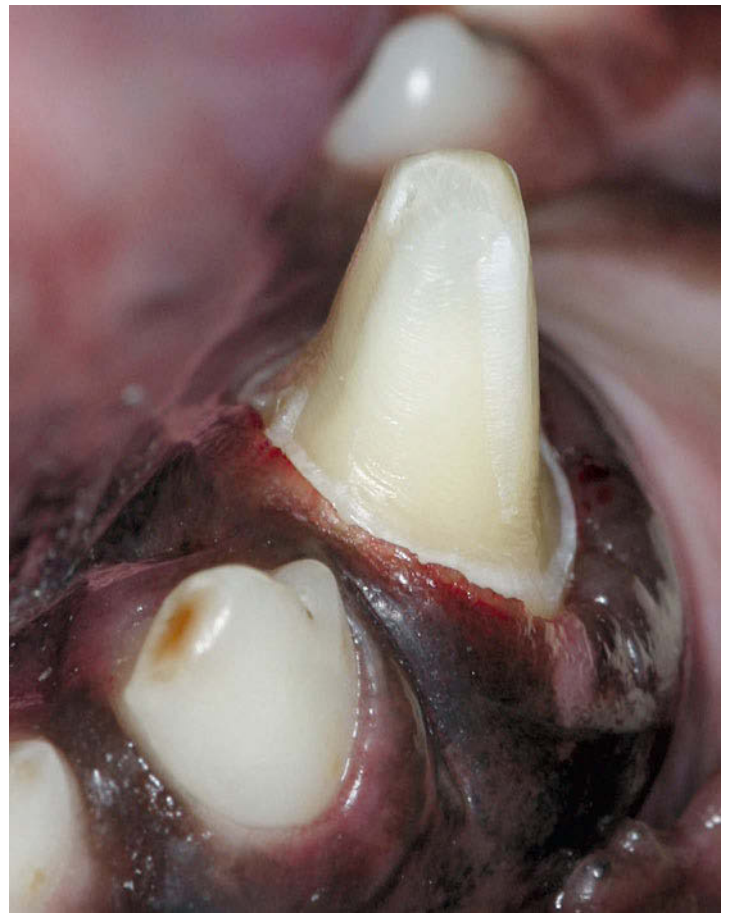
► Fig. 16.194 Follow-up presentation, crown in use. At the 6-month follow-up, the crowned mandibular canine tooth is unremarkable.

16.5.2 Ceramic Canine Crown

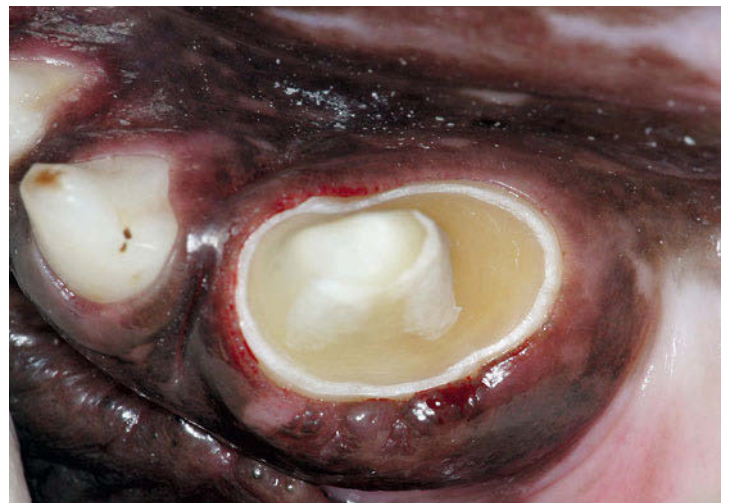A tooth-colored ceramic or a veneer crown can be used instead of a metal crown for aesthetic reasons while supporting a functional load. (► Fig. 16.195, ► Fig. 16.196, ► Fig. 16.197, ► Fig. 16.198, ► Fig. 16.199, ► Fig. 16.200, ► Fig. 16.201). Ceramic can usually withstand a load, while composite veneer crowns cannot provide sufficient stability.



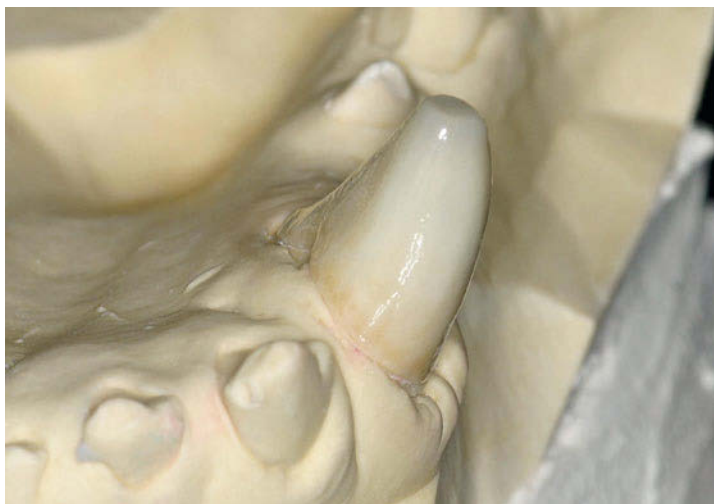
► Fig. 16.195 **Tooth 304 after root canal therapy.** Appearance of the fractured mandibular left canine tooth. Root canal therapy was performed through the fracture cavity.



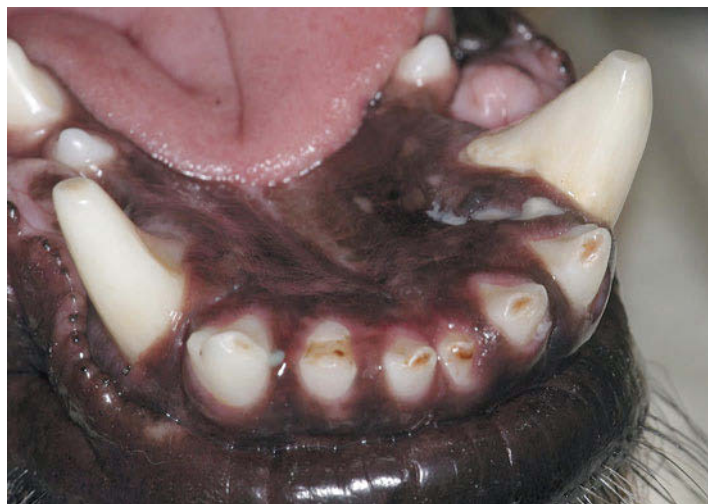► Fig. 16.196 **Preparation of the crown, mesial view.** From the mesial direction, a good cervical chamfer and the preparation border can be seen at the same time.



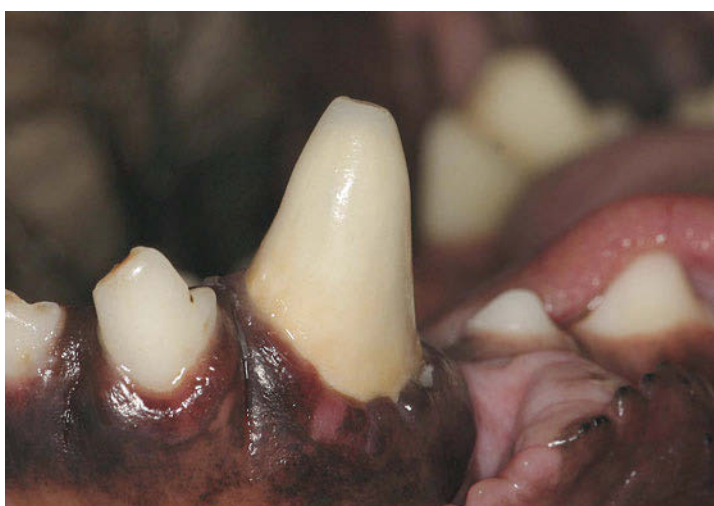► Fig. 16.197 **Preparation of the crown, occlusal view.** The entire preparation border can be seen from the occlusal direction.



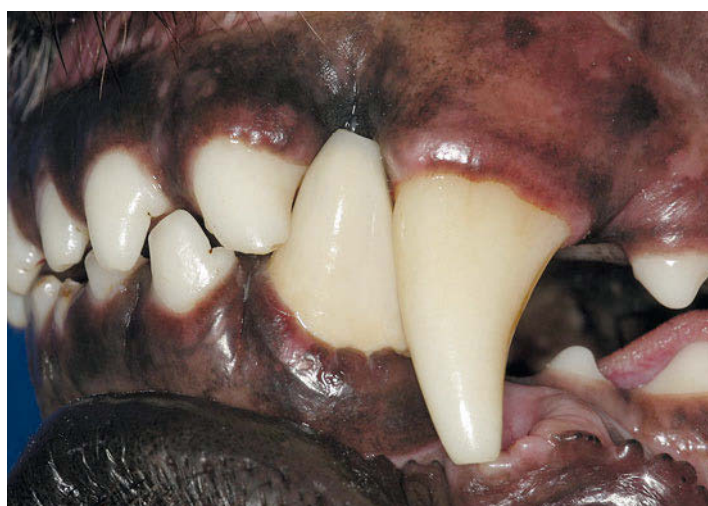► **Fig. 16.198 Ceramic crown for tooth 304 on a model.** Ceramic material is used for the crown for aesthetic reasons. The new canine crown is deliberately shorter than the original dental crown in order to optimize leverage and mitigate the loss of the artificial crown. While the crown is slightly smaller and stubbier, the abrasion of the mandibular right canine fortunately creates a visual balance.



► **Fig. 16.200 Ceramic crown of tooth 304 in situ, lingual view.** The abrasion on the mandibular right canine fortunately makes the artificial crown of the left canine tooth appear more symmetrical.



► **Fig. 16.199 Ceramic crown of tooth 304 in situ, close-up lateral view.** A ceramic crown is more visually appealing than a metal crown. The gingiva obscures the crown edge due to its cervical position.

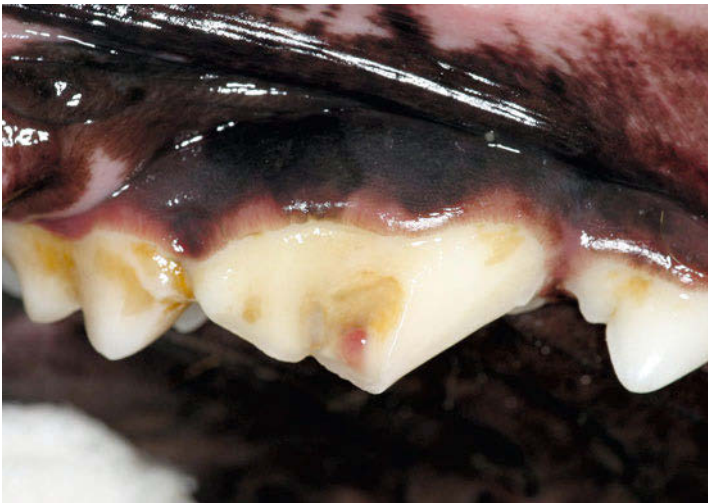

► **Fig. 16.201 Occlusion of tooth 304 with ceramic crown.** The occlusion with the maxillary teeth is unremarkable as well, since the way the carnassial tooth is guided in dogs causes the canines to lose contact immediately when the jaw is opened.

16.5.3 Carnassial Tooth Crown

Current Case

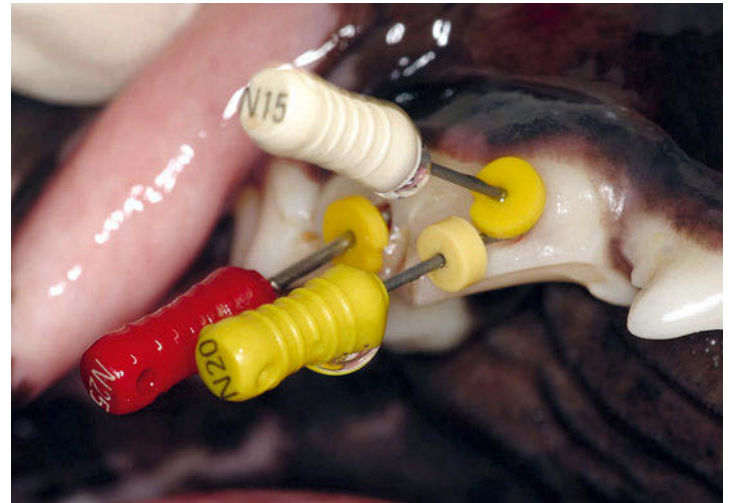
In contrast to the canine crown, in which pulling and rotational forces are most significant, the focus for a carnassial tooth crown is on shearing forces during mastication (► Fig. 16.202, ► Fig. 16.203).



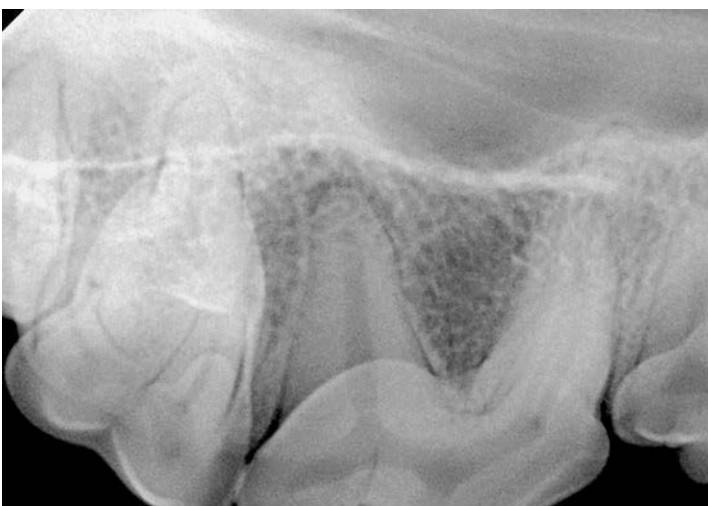► Fig. 16.202 Fractured tooth 108. A cusp fracture on the maxillary right carnassial tooth has caused pulp exposure. The calculus on the fracture area indicates that this is an older fracture. The visible pulp tissue has undergone polypoid changes.

Root canal therapy

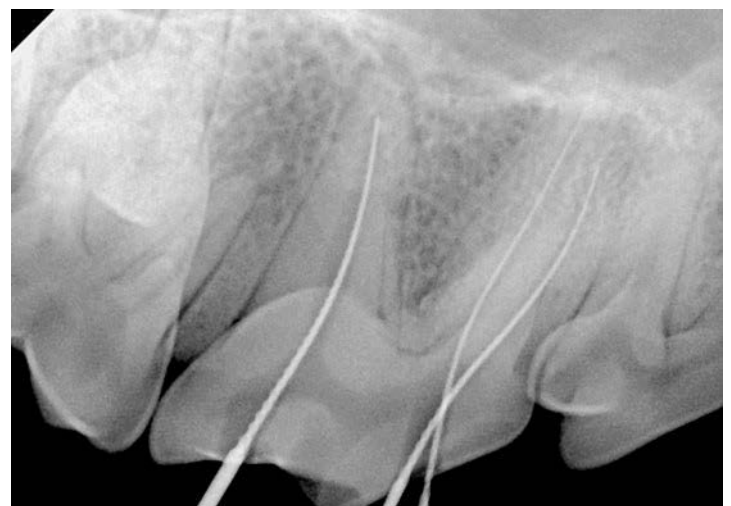
Proper root canal therapy is needed to ensure that a filling can be placed on the crown of the tooth (► Fig. 16.204, ► Fig. 16.205, ► Fig. 16.206).



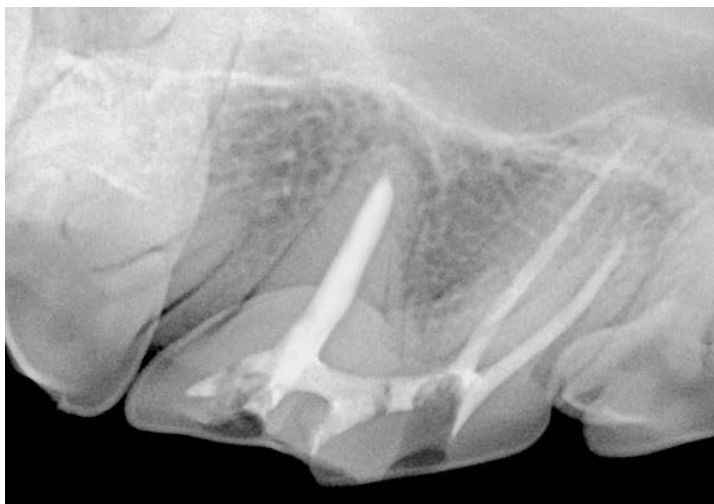► Fig. 16.204 Exploration of the root canals of tooth 108. All three root canal access points are visualized with a combined approach and files are placed in the canals for the measurement radiograph. Combined access on the maxillary carnassial tooth means that the distal canal is visualized separately and the two mesial canals are visualized by way of a common buccal cavity. No palatal access is provided via the very small palatal cusp.



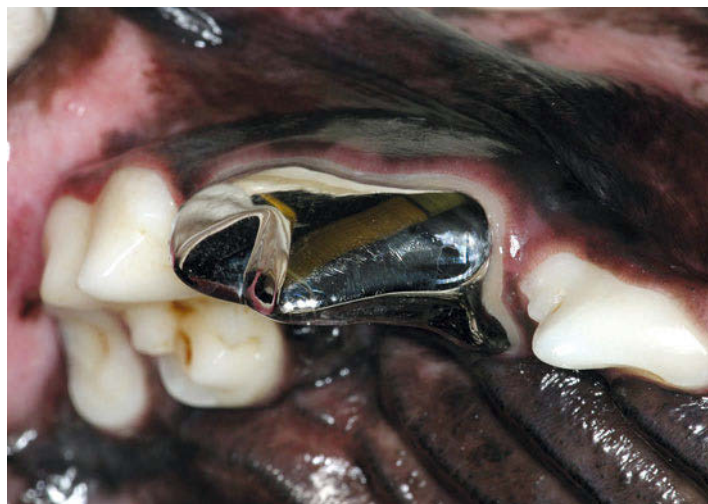► Fig. 16.203 Radiograph of tooth 108. The distal root shows a low-grade osteolysis process.



► Fig. 16.205 Measurement radiograph of tooth 108. In the measurement radiograph, all files reach the end of their respective root canal. A distal projection allows the two mesial root canals to be visualized independently of one another (parallax method).



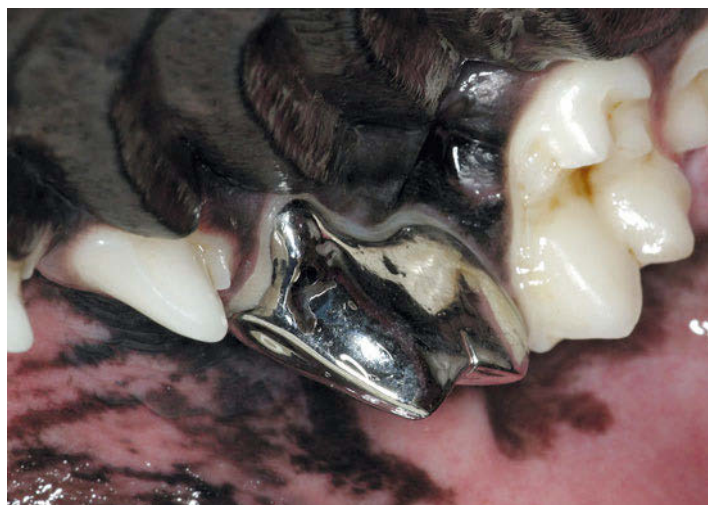
► **Fig. 16.206 Postoperative radiograph of the root canal filling of tooth 108.** The root canal filling is homogeneous in the intraoperative radiograph and provides a base for applying a crown.



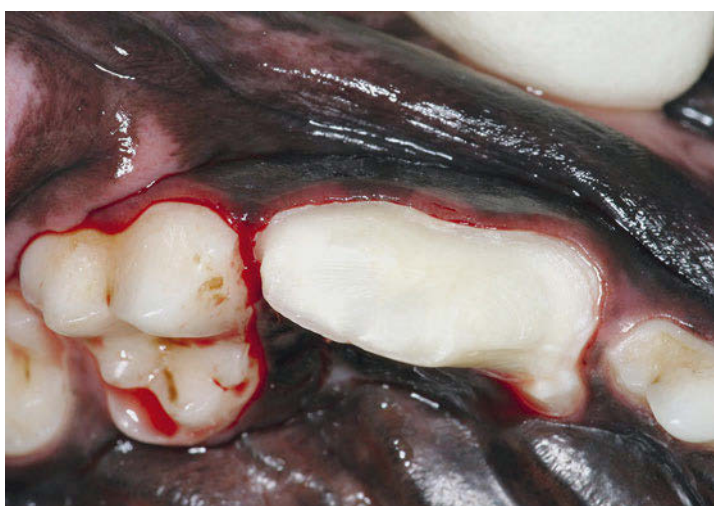► **Fig. 16.208 Crown in situ from the mesiolateral direction.** The crown margin runs parallel to the gingival margin. If possible, the crown margin should be placed supragingivally in order to keep the gingiva healthy and prevent inflammation.

Coronal Filling

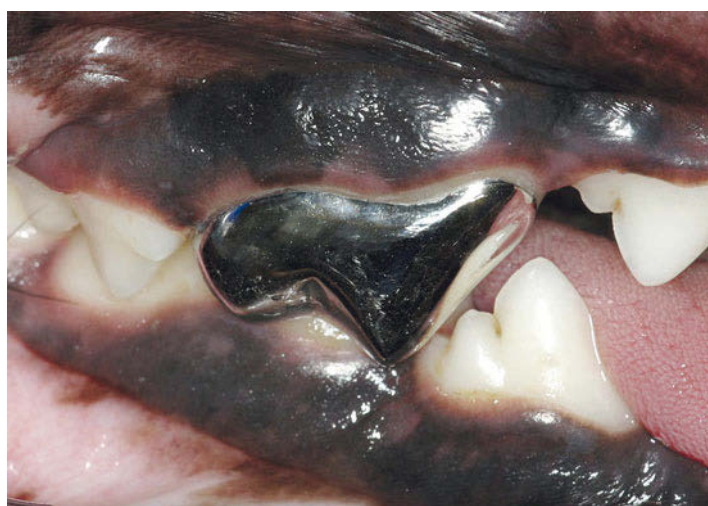► Fig. 16.207, ► Fig. 16.208, ► Fig. 16.209 and ► Fig. 16.210 show the final coronal filling.



► **Fig. 16.209 Crown in situ from the palatal direction.** The course of the gingiva is also followed palatally.



► **Fig. 16.207 Crown preparation.** The preparation of the crown includes the entire circumference of the tooth and the small palatal cusp.



► **Fig. 16.210 Crown in occlusion.** With the teeth in terminal occlusion, the jaw should be checked for proper closing to eliminate possible interfering contacts on the crown.